

Combining systemic retinoids with biologic agents for moderate to severe psoriasis

Elizabeth C. A. Smith, MD, Christy Riddle, MD, M. Alan Menter, MD, and Mark Lebwohl, MD

From the Department of Dermatology, Mount Sinai School of Medicine, New York and Baylor University Medical Center, Dallas, Texas

Correspondence

Elizabeth C. A. Smith, MD
c/o Victoria White
Department of Dermatology
Mount Sinai School of Medicine
One Gustave L. Levy Place
Box 1048
New York, NY 10029
E-mail: elizabeth.smith@mssm.edu

Abstract

Background Moderate to severe psoriasis, which is defined as psoriasis affecting more than 20% of the body surface area, often requires a combination of therapies to achieve remission. Although numerous data exist regarding the use of acitretin and biologic agent therapy alone for psoriasis, little is known about the efficacy, safety, and tolerability of acitretin combined with biologic agents.

Methods Fifteen patients with psoriasis treated with concomitant acitretin and a biologic agent were identified, and their charts were reviewed for response to therapy, additional therapy necessary for disease management, side-effects, and laboratory abnormalities whilst on combination therapy. The Institutional Review Board did not require approval for this chart review.

Results Twenty-nine per cent of patients showed clearance of psoriasis, 43% of patients showed an improvement of 90%, 14% showed an improvement of 75%, and 7.1% showed no change. During treatment with acitretin and biologic agent, five patients required no adjunctive treatment. Three patients were able to stop narrow-band ultraviolet-B (UV-B) therapy after an average of 2.33 months of combination therapy. Only one patient continued to require phototherapy (UV-B) in addition to the biologic agent. Three patients developed squamous cell carcinoma (SCC) whilst on combination therapy, but all patients had a previous history of SCC. One patient developed non-Hodgkin's lymphoma after 3 years of etanercept and acitretin, and the etanercept was discontinued.

Conclusions Acitretin combined with biologic agents offers a promising method of managing refractory psoriasis. More research is needed to determine the long-term safety and efficacy of this combination.

Introduction

Psoriasis, a disease that affects approximately 2% of the population, often presents a therapeutic challenge to the physician.¹ Although the majority of cases are mild and respond in different degrees to topical therapy, 25% of psoriasis patients require systemic treatment, phototherapy, or both.² Until recently, the only approved systemic therapies were psoralen plus ultraviolet-A (PUVA), methotrexate, cyclosporin, and acitretin.³ With the emergence of new biologic therapies, dermatologists now have a wider array of tools for use against this lifelong disease. The mechanism of action of the traditional systemic agents is different from that of biologic agents, suggesting that, when combined, these therapies may have an additive effect.⁴ Thus, data are needed to determine the safety, tolerability, and efficacy of biologic agents when they are added to the other available systemic

therapies. Although data exist regarding the combination of methotrexate and biologic agents, there is little experience with cyclosporin or acitretin when combined with biologic agents.²

The ideal combination of medications for psoriasis would achieve a better control of the disease than with either agent alone and would minimize toxicity. The main side-effects of the systemic therapies used in psoriasis can be classified into four broad categories. The first, immunosuppression, is a complication of most therapies used to treat psoriasis, including methotrexate, cyclosporin, and biologic agents. Biologic agents may be less immunosuppressive than traditional agents because they target specific processes in the pathogenesis of psoriasis, but must obviously still be used with caution. An analysis of 180 patients receiving etanercept showed serious infections in some subjects, such as psoas abscess, septic joints, and bacteremia.⁵ Infliximab also has a history of increasing infection rates in patients, as demonstrated by

increased rates of tuberculosis,⁶ and cases of cryptococcal infection⁷ and staphylococcal endocarditis.⁸ The only class of systemic therapy that is not immunosuppressive is the retinoids. Thus, intuitively, acitretin and biologic agents, when combined, should be the least immunosuppressive of the potential systemic combinations; however, more studies are necessary to document this.⁴

The second major category of side-effects is organ toxicity, i.e. bone marrow, liver, and renal. Methotrexate has been proven to suppress the bone marrow. Both methotrexate and acitretin are potentially hepatotoxic, although acitretin hepatotoxicity is far less common, with liver biopsy not required. Cyclosporin can be nephrotoxic, limiting its use to 1 year of continuous therapy, and in patients with renal disease and/or hypertension. At least two of the biologic agents, infliximab and etanercept, have been tested with methotrexate and show no additional bone marrow toxicity or harm to the liver, but more studies are needed with regard to the combination of cyclosporin or acitretin with these medications.⁴

The third category of side-effects is carcinogenicity and photocarcinogenicity. To date, there is little conclusive evidence of an increased risk of lymphoproliferative malignancy in patients receiving biologic therapy alone, but data collection over the decades to come will determine whether that remains the case.⁹ One series reported seven patients who developed squamous cell carcinoma (SCC) after starting etanercept therapy,¹⁰ and more data are necessary to determine whether the biologic agents increase the risk of cutaneous malignancy. As cutaneous carcinogenesis is a concern of biologic therapy, it will be interesting to see whether retinoids may potentially reduce this risk, as they have done with cyclosporin in the transplant population.¹¹

The final category of side-effects, teratogenicity, is the primary side-effect of retinoids, such as acitretin. The duration of teratogenic potential of acitretin is increased when the drug is combined with ethanol, and this fact has limited the use of retinoids in women of childbearing potential. Biologic agents, being either Pregnancy Category B or C, offer an option that, to date, shows no evidence of harm to developing fetuses.⁴

Thus, from the above side-effect categories of the drugs, retinoids and biologic agents hold much promise for combination therapy, given their divergent toxicities and mechanisms of action. Studies are needed to determine whether these combinations are safe and effective alternatives for patients with refractory psoriasis. To date, there has been only one published case series of eight patients on biologic agents and acitretin. Six of these patients took acitretin and etanercept, one took adalimumab and acitretin, and one took alefacept and acitretin. These patients tolerated therapy without significant adverse events, but more data are needed to determine the long-term safety and efficacy.¹² We report 15 additional patients treated with acitretin and a biologic agent.

Materials and Methods

The medical records of the clinical course of 15 patients with psoriasis treated with concomitant acitretin and biologic therapy were reviewed. The charts were examined for demographic data, previous psoriasis therapies, combination regimens, adjunctive treatments used whilst on acitretin and a biologic agent, and laboratory abnormalities. The patients were followed up by one of two physicians throughout their therapy. The physician global assessments were recorded, with psoriasis evaluated on a scale of 0–3 (0, clear; 1, mild disease; 2, moderate disease; 3, severe disease). At each visit, the physician also assessed the percentage improvement from baseline prior to any therapy. Outcome measures included the response of psoriasis to the combination of medications, the amount of additional therapy necessary to control the disease, and the side-effects noted whilst the patients were on the dual regimen.

Results

There were five women and 10 men with a mean age of 50.15 years. All patients were treated with acitretin in addition to a currently approved biologic agent. Eleven were treated with alefacept, four with etanercept, and two with infliximab followed by adalimumab. The average time of treatment of the patients with retinoid combined with the biologic agent was 7.28 months.

During acitretin monotherapy, one patient worsened, four showed no change, two showed 50% improvement, and two showed 90% improvement. The doses of acitretin ranged from 10 to 50 mg/day. The patients' disease responded well to combination therapy. When the biologic agent was added, four patients experienced complete clearance, six patients experienced 90% improvement, two showed 75% improvement, one improved by 50%, and one showed no change (see Fig. 1).

Ninety percent improvement was noted in one patient treated with a combination of infliximab and acitretin over a 3-month period. Infliximab was then discontinued because of the development of serum sickness leading to recurrence of the disease. Adalimumab was added to the regimen, and the patient again showed a 90% response rate. One patient developed SCC on his left arm after 1 month on a combination of etanercept and acitretin; however, this patient had a history of SCC prior to commencing biologic therapy. One patient developed SCC *in situ* whilst on alefacept and acitretin, but, again, this patient had a previous history of SCC. One patient with a history of SCC was started on etanercept, and continued to develop multiple SCCs. Acitretin was added at 25 mg every other day, and she continued to develop multiple SCCs; however, the rate decreased from an average of three SCCs diagnosed every 2 weeks to only actinic keratosis for 18 months. Actinic keratosis was treated with cryotherapy

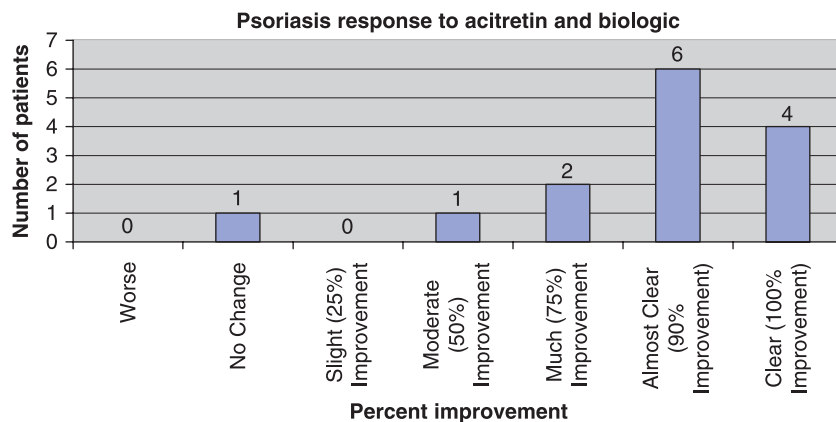


Figure 1 Response of psoriasis to acitretin and biologic agent

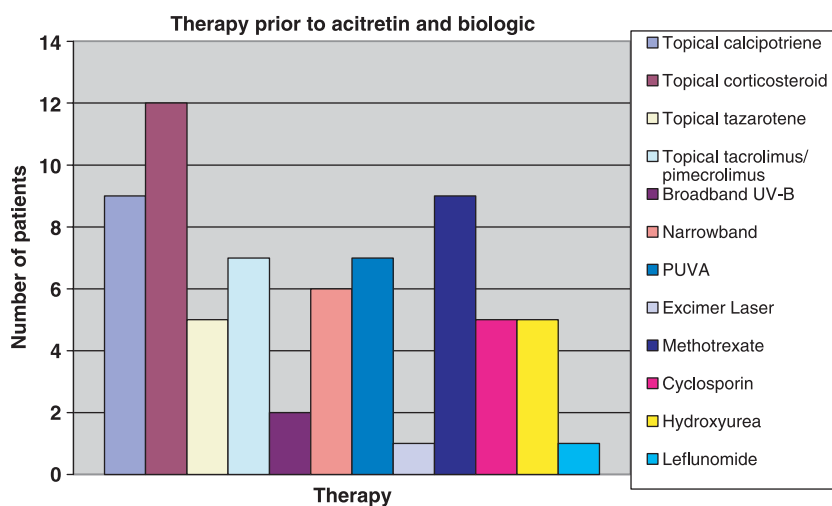


Figure 2 Therapy prior to acitretin and biologic agent. PUVA, psoralen plus ultraviolet-A

and topical fluorouracil. Two patients developed mild upper respiratory infections whilst on alefacept and acitretin, but both resolved spontaneously. Two patients developed mild headaches after alefacept infusions, but both resolved with acetaminophen. One patient was on etanercept and acitretin for 3 years, but his etanercept therapy was halted when he developed non-Hodgkin's lymphoma.

Prior to this combination therapy, many other treatment modalities had been used in these patients (see Fig. 2). During treatment with acitretin and a biologic agent, five patients required no adjunctive therapy. Three patients were able to discontinue narrow-band ultraviolet-B (UV-B) therapy after 4 months on etanercept, 1 month on alefacept, and 2 months on alefacept, respectively. Only one patient continued to require UV light therapy (UV-B) whilst on combination treatment. One patient continued to take hydroxyurea whilst on combination therapy. Four patients stopped taking acitretin after an average of 1.62 months on biologic therapy (see Fig. 3).

Eleven patients developed triglyceride or cholesterol elevation whilst on acitretin, with one patient requiring ator-

vastatin therapy. Two patients showed triglyceride elevations in the 201–250 mg/dL range, three in the 301–350 mg/dL range, and one above 350 mg/dL. Hypercholesterolemia was found in nine patients at some point during therapy. Two patients had cholesterol in the 181–210 mg/dL range, two in the 211–240 mg/dL range, three in the 241–270 mg/dL range, one in the 271–300 mg/dL range, and one above 300 mg/dL. Two patients developed mild gammaglutamyl transpeptidase elevations of 68 and 73 U/L, respectively (normal range, 8–50 U/L).

Only one patient on alefacept showed significantly depressed CD4 T-cell counts. This patient had CD4 counts of 201, 116, and 124/ μ L, which necessitated withholding his alefacept infusions on three weekly occasions. No other patients had CD4 counts below 367/ μ L.

All of the 11 patients taking alefacept and acitretin completed the 12-week course of medication. All of the patients taking etanercept continued this medication, with the exception of the patient who developed non-Hodgkin's lymphoma, as discussed above.

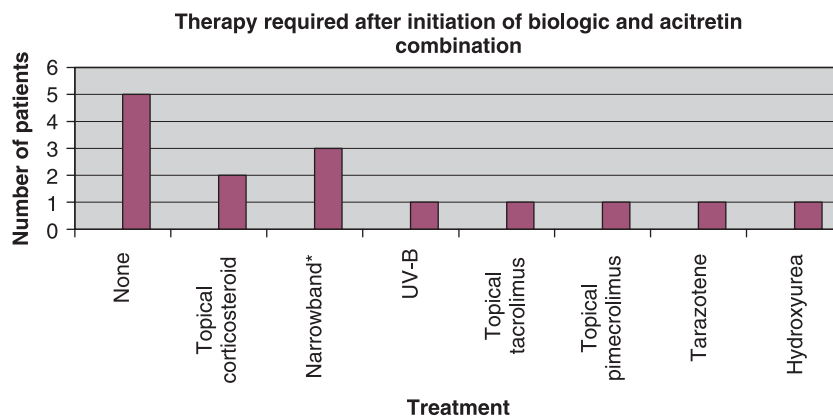


Figure 3 Therapy required after the initiation of biologic agent and acitretin combination. *All narrow-band patients discontinued therapy whilst on a combination of biologic agent and acitretin

Conclusion

Although this is a small retrospective review of only 15 patients treated with acitretin and biologic agents, the results confirm our clinical impression that this combination is a promising method for the treatment of refractory psoriasis. Prior to this combination, all patients had tried multiple topical therapies: 60% had taken methotrexate, 30% had taken cyclosporin, and 46% had received PUVA therapy. After treatment with the combination of medications, 38% were able to stop all additional therapy, 23% were able to stop acitretin, and 23% were able to discontinue narrow-band UV-B therapy. Only one patient continued phototherapy after starting the combination, but this patient had not finished his course of alefacept. Thus, the patients' disease was managed with much less topical and light therapy than required previously. Light therapy and topical treatments can be very time intensive, with one study reporting that patients spend up to 26 min a day on topical treatments.¹¹ Hence, not only did the combination treatment reduce the number of medications used to treat the disease, it also decreased the time commitment on the part of the patient.

Most importantly, the disease responded remarkably well to combination therapy. Although only two patients achieved 90% clearing with acitretin alone, combination with a biologic agent achieved 90% clearing in six patients and 100% improvement in four. Alefacept does not achieve its maximum effect until 16 weeks after the first infusion,⁴ and five of the alefacept and acitretin-treated patients in our study had not reached that time frame. In addition, second courses of alefacept as monotherapy yield more significant Psoriasis Activity and Severity Index (PASI) 75% and PASI 50% improvement than a single course. Thus, it is likely that patients on combination therapy will develop even better responses over time.

The side-effects experienced by the patients were most significant for the development of serum sickness in the single infliximab and acitretin-treated patient, the development of

non-Hodgkin's lymphoma in a patient treated with etanercept and acitretin, and the occurrence of SCCs in three others. There are no documented cases of serum sickness development in patients on acitretin therapy, but there are numerous reports of this condition in patients receiving infliximab infusions. A recent review of 18,572 rheumatoid arthritis patients compared patients on traditional therapy with those on tumor necrosis factor (TNF) antagonists. The patients on TNF antagonists developed lymphoma at a slightly higher rate, but the difference was small.¹³ Further long-term studies are warranted to determine whether there is an increased risk of lymphoma in patients treated with TNF- α blockers. Acitretin has not been proven to increase the risk of lymphoproliferative malignancy. The possible increased risk of SCC in patients receiving etanercept has been discussed previously, although one study failed to demonstrate an increase in rheumatoid arthritis on etanercept.¹⁴ All of the patients who developed SCC had previous histories of this cutaneous malignancy, and further studies are needed to determine the risk of cutaneous malignancies with biologic therapy. A recent case report and literature review indicates that acitretin suppresses the development of SCC in PUVA patients, and should be considered for suppressive therapy in psoriasis patients who develop SCC as a result of PUVA.¹⁴ If further studies determine that biologic agents increase the risk of SCC, acitretin may be a suppressive therapeutic option for affected individuals.

In summary, our patients tolerated the short-term combination of acitretin and biologic agents extremely well, with 75% obtaining improvement of 90% or greater. Further studies are needed to evaluate the long-term safety, efficacy, and remission rates of this combination of medications, as well as the role of adding retinoid therapy to patients on existing biologic drugs in an attempt to improve efficacy, i.e. PASI scores, and to potentially reduce the cost.

Conflicts of interest

Dr Smith and Dr Riddle have no conflicts of interest to disclose.

Conflict of interest list

Company Name	Relationship	Compensation
Abbott Laboratories	A, C, I, S	G/H
Amgen	A, C, I, S	G/H
Astralis	A, C, I	G/H
Centocor	A, C, I, S	G/H
Galderma	A, C, I, S	G/H
Genentech	A, C, I, S	G/H
Novartis	A, C, I	G/H
PharmaDerm	O	G/H
Stiefel	A, C, I, S	H
UCB	C	H
Warner Chilcott	A, C, I, S	G/H

Relationship: A = Advisory Board; C = Consultant; I = Investigator; O = Other; S = Speaker.
Compensation: G = Grant; H = Honorarium.

Dr Menter's conflicts of interest are as follows. Research: Abbott, Allergan, Allermid, Amgen, Astralis, Biogen, Centocor, Connetics, Corixa, Dermik, Dow, Ferndale, Fujisawa, Galderma, Genzyme, GlaxoSmithKline, Inamed, Lumenis, Medicis, Novartis, Otsuka, Photocure, Regeneratio, Pharma AG, Scirex, Serono, Thermosurgery. Consultancies and Honoraria: Allergan, Amgen, Biogen, Centocor, Genentech, ICN, Novartis, Serono, Thermosurgery, Warner-Chilcott. No stock ownership.

Dr Mark Lebwohl has been a consultant, speaker on investigator for Abbott, Amgen, Astellas, Centicor, Genentech, Stiefel, Galderm, Novartis, PharmaDerm, Warner Chilcott.

References

- Shaw JC. Overview of psoriasis. *UpToDate* 2003. URL www.uptodate.com [accessed on September 2003].
- Cather JC, Menter A. Combining traditional agents and biologics for the treatment of psoriasis. *Semin Cutan Med Surg* 2005; 24: 37–45.
- Lebwohl M, Saud A. Treatment of psoriasis. Part 2. Systemic therapies. *J Am Acad Dermatol* 2001; 45: 649–661.
- Lebwohl M. Combining the new biologic agents with our current psoriasis armamentarium. *J Am Acad Dermatol* 2003; 49: 118–124.
- Phillips K, Husni ME, Karlson EW, et al. Experience with etanercept in an academic medical center. Are infection rates increased? *Arthritis Rheum* 2002; 47: 17–21.
- Keane J, Gershon S, Wise RP, et al. Tuberculosis associated with infliximab therapy, a tumor necrosis factor alpha neutralizing agent. *N Engl J Med* 2001; 344: 1099–1100.
- True DG, Penmetcha M, Peckham SJ. Disseminated cryptococcal infection in rheumatoid arthritis treated with methotrexate and infliximab. *J Rheumatol* 2002; 29: 1561–1563.
- Reichardt P, Dahnert I, Tiller G, et al. Possible activation of an intramyocardial inflammatory process (*Staphylococcus aureus*) after treatment with infliximab in a boy with Crohn's disease. *Eur J Pediatr* 2002; 345: 1098–1104.
- Brown SL, Greene MH, Gershon SK, et al. Tumor necrosis factor antagonist therapy and lymphoma development: twenty-six cases reported to the Food and Drug Administration. *Arthritis Rheum* 2002; 46: 3151–3158.
- Smith KJ, Skelton HG. Rapid onset of cutaneous squamous cell carcinoma in patients with rheumatoid arthritis after starting tumor necrosis factor alpha receptor IgG1 fusion complex therapy. *J Am Acad Dermatol* 2001; 45: 953–956.
- Stockfleth E, Ulrich C, Meyer T, et al. Epithelial malignancies in organ transplant patients: clinical presentation and new methods of treatment. *Recent Results Cancer Res* 2002; 160: 251–258.
- Conley J, Nanton J, Dhawan S, et al. Novel combination regimens: biologics and acitretin for the treatment of psoriasis – a case series. *J Dermatol Treat* 2006; 17 (2): 86–89.
- Wolfe F, Michaud K. Lymphoma in rheumatoid arthritis: the effect of methotrexate and anti-tumor necrosis factor therapy in 18,572 patients. *Arthritis Rheum* 2004; 50: 1740–1757.
- Lebwohl M, Blum R, Berkowitz E, Kim D, Zitnik R, Osteen C, Wallis WJ. No evidence for increased risk of cutaneous squamous cell carcinoma in patients with rheumatoid arthritis receiving etanercept for up to 5 years. *Arch Dermatol* 2005; 141: 861–864.
- Lebwohl M, Tannis C, Carrasco D. Acitretin suppression of squamous cell carcinoma: case report and literature review. *J Dermatol Treat* 2003; 14: 3–6.